


# Smile symmetry and harmony

**Haroon Latiff** presents a case in which a young man was treated with alignment, bleaching and composite bonding with the 'reverse triangle' technique, to achieve a dramatic, but conservative, smile transformation

**Dr Haroon Latiff BDS PGCert**  
Dentist



A 21-year-old male attended Dental Elegance because he did not like the interdental gaps in his upper arch. He was also self-conscious about the crooked lower front dentition, and the colour and irregular shape of his teeth (Figure 1).

## Clinical and orthodontic assessment

A full examination was carried out to ensure his teeth and gingivae were healthy. No carious lesions were detected, normal bone levels were observed, and the root morphology of his teeth appeared normal.

Oral hygiene was fair, although gingival inflammation and mild plaque deposits were noted, palatally and lingually. His teeth were a mixture of A2 and A3 on the Vita shade guide.

The orthodontic assessment revealed a class I skeletal pattern, average Frankfort-mandibular plane angle (FMFA) and lower face height. The patient's chin deviated to the left, he had a high lip line, a normal nasolabial angle and competent lips.

A normal gingival biotype was recorded but the lower gingival zenith levels were uneven in the anterior segment (Figures 2 to 4).

A class I incisor relationship was observed, with a molar relationship of 0.5 unit class III on the right and left (Figure 5). Meanwhile, the canine relationship was 0.25 unit class III on the right and class I on the left.

The patient had an overjet of less than 1mm, with an overbite of 60% overlap (Figure 6).

An anterior crossbite was discovered on the LL3 (Figure 7). No displacement on closure was reported. Crowding of 2.8mm was recorded in the lower arch, and spacing was noted in the upper arch. The lower midline had shifted to the left by 1mm (Figure 8).

**After sending the impressions to the laboratory, a 3D digital image was provided to show the patient's teeth post treatment**

## Treatment choices

After carrying out the clinical examination, the treatment choices were presented to the patient. The options ranged from doing nothing, straightening the teeth with comprehensive orthodontics or anterior alignment followed by bleaching and bonding (ABB), to ceramic veneers.

Doing nothing was not an option that the patient wanted to consider, as he was very keen to improve the appearance of his front teeth.

He selected the ABB approach as it was the most

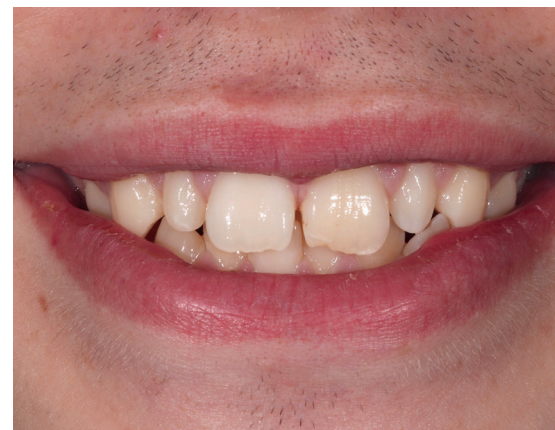minimally invasive cosmetic treatment that would completely transform his smile without the need for injections or drilling.

Ceramic veneers would have been too invasive and, as fixed braces did not appeal to him, he was not keen on comprehensive orthodontics with a specialist.

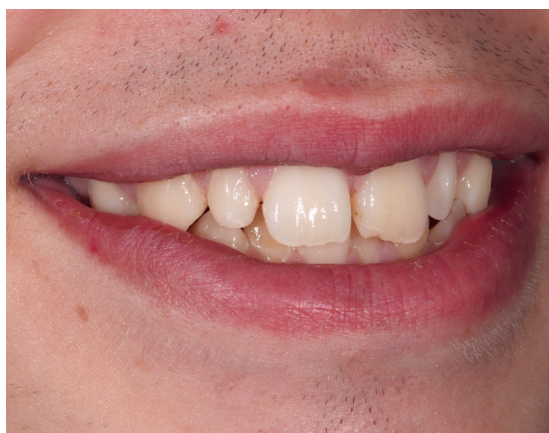As the posterior segments were satisfactory, it was agreed to carry out anterior alignment orthodontics. The patient simply wanted to improve the six anterior upper and lower teeth (Figures 9 and 10).



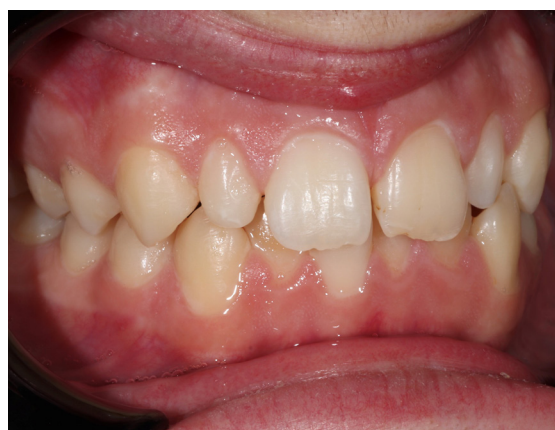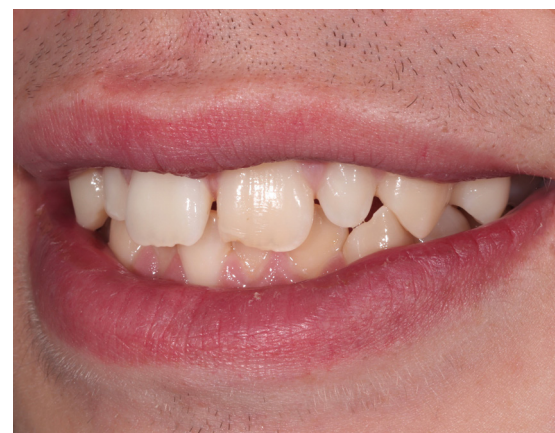**Figure 1:** The patient was self-conscious about the gaps in between his teeth, as well as their irregular shapes and colour. He also didn't like his crooked lower front teeth



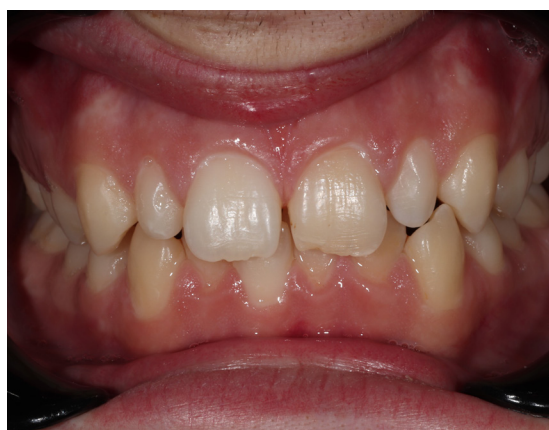**Figure 2:** Front-on smile view



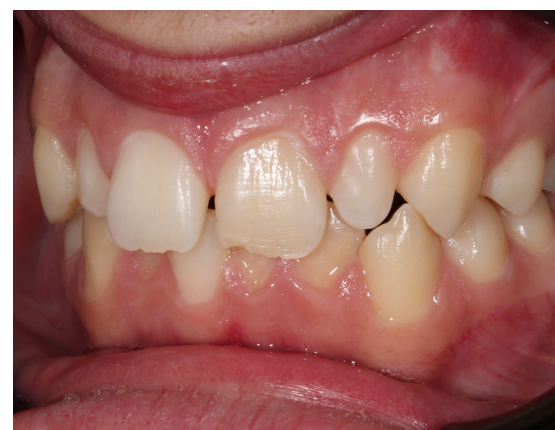**Figures 3 and 4:** Side-on smile views



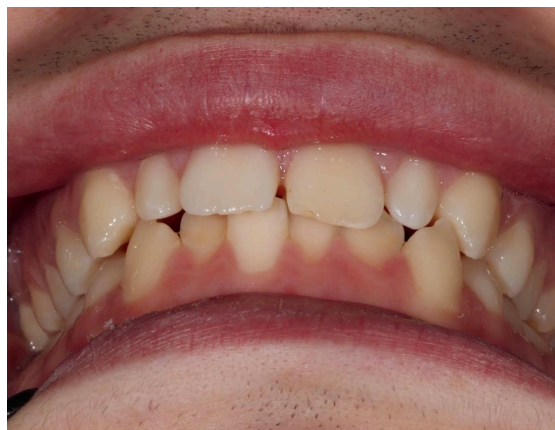**Figure 5:** A class I incisor relationship was observed, with a molar relationship of 0.5 unit class III on the right and left



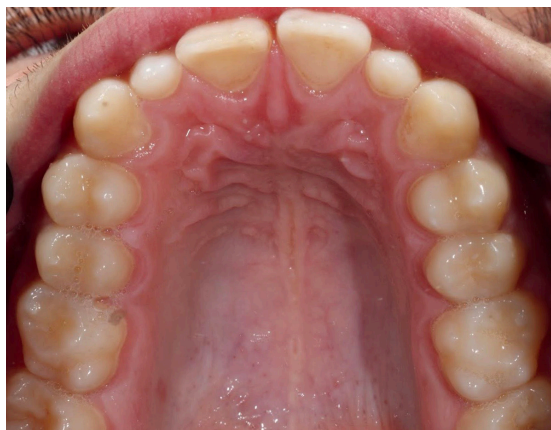**Figure 6:** The patient had an overbite of 60% overlap



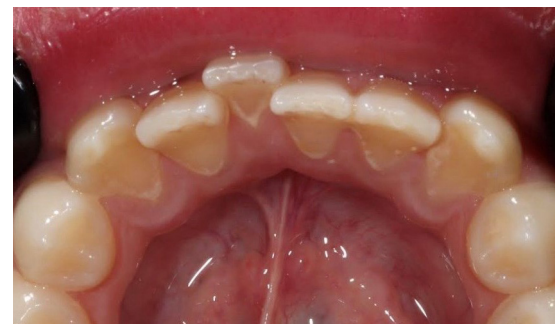**Figure 7:** An anterior crossbite was discovered on the LL3



**Figure 8:** The lower midline had shifted to the left by 1mm



**Figures 9 and 10:** Crowding of 2.8mm was recorded in the lower arch. The patient wanted to improve the six anterior upper and lower teeth



Once the teeth had been straightened, home whitening would be carried out, followed by composite bonding to the six upper front teeth.

### Rapid alignment

Before commencing treatment, the patient attended a one-hour hygiene appointment to remove the plaque deposits and improve his oral hygiene. A two-stage putty-wash technique was then applied to capture teeth and soft tissue impressions for the laboratory analysis.

For the quickest and most efficient result, Clearsmile aligners were chosen to treat the upper arch, and a Super Slim Inman Aligner was selected for the lower arch.

A week after sending the impressions to the laboratory, a 3D digital image was provided to show the patient's teeth post treatment. The visual was presented to him before confirming the construction of the appliances.

Using a 37% phosphoric acid etch, a small composite button was placed on the lingual surface of the LR2 to activate the lingual bow of the Inman Aligner and push out the tooth.

Kulzer Venus Pearl A2 shade was used for the composite button, as the material is easy to manipulate and shape. Interproximal reduction (IPR) was carried out on the LR4 to LL4 following the

### It was agreed to create more angular-shaped teeth to give him a more masculine, confident appearance

laboratory's prescription, to allow the teeth to move as planned. The upper arch corrections were simple enough to achieve without IPR or attachments.

Instructions were given to the patient on the appliances' wear schedule. He was asked to return every two weeks for each new aligner and further IPR to the lower arch, before the placement of a buccal composite button on the LR1. The orthodontic treatment took a little over two months to complete.

### Whitening and tooth preparation

A scan was taken at the practice to assist with laboratory construction of the Intelligent Alignment Systems (IAS) upper and lower bleaching trays. Home whitening was carried out using Philips Zoom! Daywhite 6% hydrogen peroxide. The daily 35-minute regime was completed within two to three weeks with no sensitivity. The patient's dentition eventually reached B1 on the Vita shade guide.

Two weeks after whitening was completed,

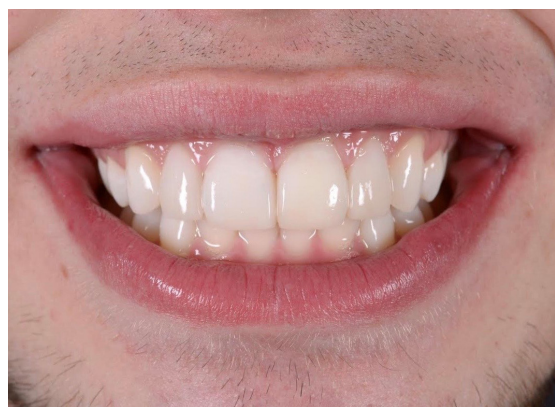composite bonding was carried out from the UR3 to the UL3. Before commencing treatment, the various possible shapes were discussed with the patient. It was agreed to create more angular-shaped teeth to give him a more masculine, confident appearance.

Cotton wool rolls and a saliva ejector were positioned to isolate the adjacent dentition. The front six teeth were cleaned using oil-free prophylaxis paste. Composite bonding commenced on the UR1, which was used as a guide for shaping the other teeth, aiding visualisation of the end result throughout the procedure. The UR1 was sandblasted with 27-micron aluminium oxide powder and then washed and dried.

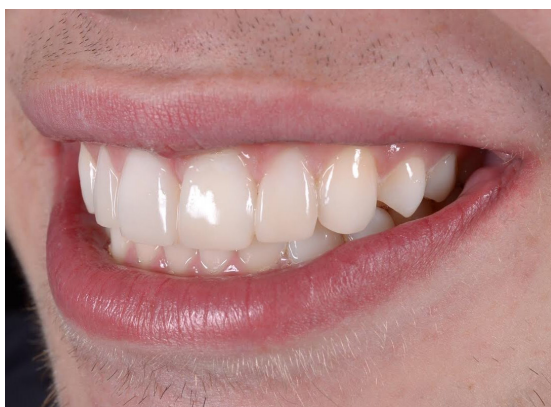Each tooth was conditioned with 37% phosphoric acid etch for 30 seconds before being washed and dried thoroughly again. Once the teeth were completely dry, a total-etch, single-component dental adhesive was applied and gently air dried for five seconds, followed by light curing for 20 seconds.

### Outstanding aesthetics and strength for anterior composite cases

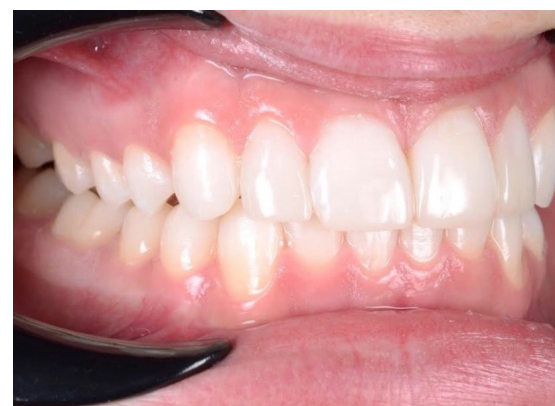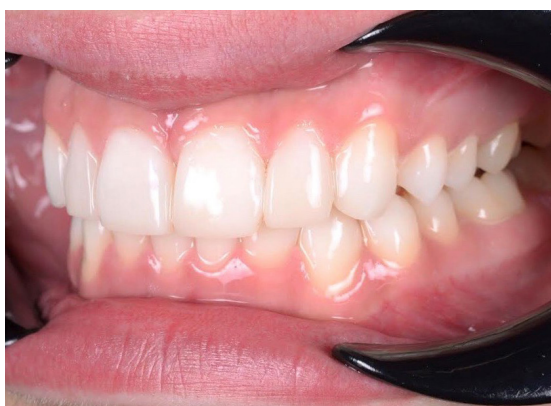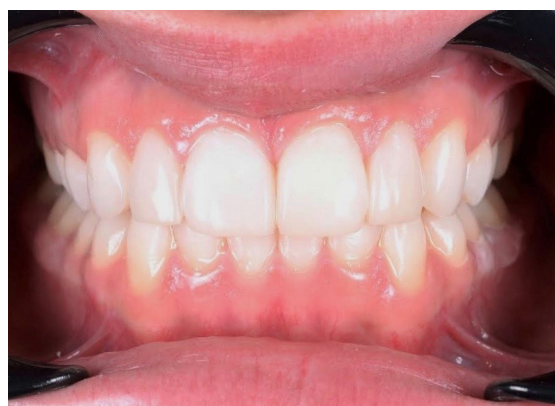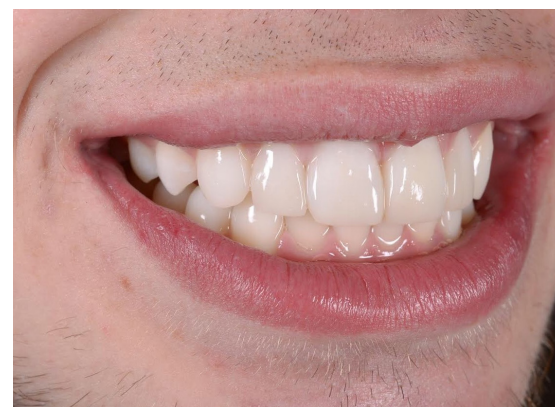Kulzer Venus is my composite of choice for anterior cases, due to its outstanding aesthetics and strength. I genuinely believe that no other brand of composite can offer such an effective combination of both qualities. ▶



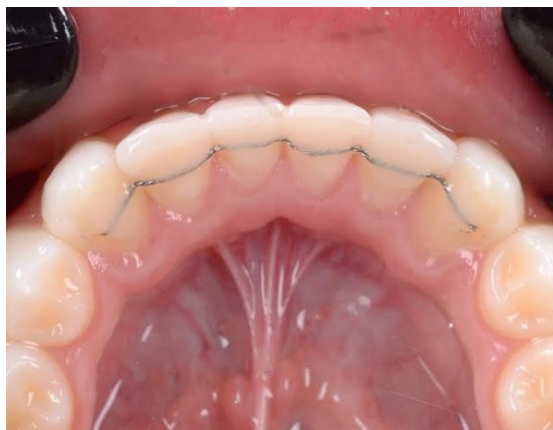**Figure 11:** Venus Diamond consistently produces a superior finish



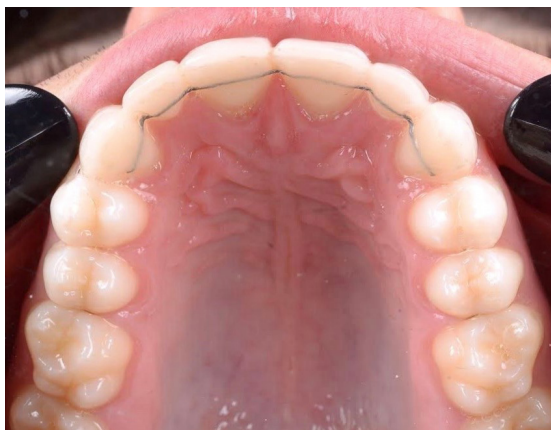
**Figures 12 and 13:** Once the UR1 shape was satisfactorily completed, the process was repeated on the remaining teeth



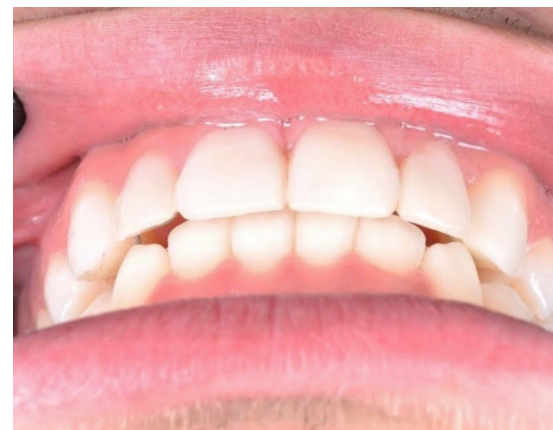**Figures 14, 15 and 16:** The front six teeth were polished using All Surface Access Polishers (ASAP) wheels and a felt wheel with polishing paste to create a high lustre



**Figure 17:** Venus Diamond Flow was used for its excellent strength and flowability to bond the lower wire retainer



**Figure 18:** Thin sections of Venus Pearl, with its easy manipulation and higher wear resistance, were used to bond the upper wire retainer



**Figure 19:** The dramatic transformation was quickly achieved with a conservative approach

Venus Diamond's firmness enables placement of the individual layers freehand without the material slumping, and it consistently produces a superior finish (Figure 11).

I am a passionate believer that the best things in life are simple!

The IAS reverse triangle technique was used to place the composite. The method is an extremely straightforward way of layering composite bonding and seems to work particularly well with Venus.

The technique involves placing the composite in two separate dentine and enamel layers. The dentine layer forms the palatal shell, while also comprising the main body of the restoration. The material needs to be thickest at the margin between the composite and tooth, and thinnest at the incisal edge.

Once the dentine layer has been placed, the enamel layer is applied over the surface of the dentine layer, with a little overlap onto the tooth surface. This second layer needs to be thinnest at the margin and thickest at the incisal edge.

In this case, the dentine layer was built up using Venus Diamond Opaque Light (OL) shade. It was followed by build-up of the interproximal walls and enamel layer with Venus Diamond B1 shade.

I have never been asked by a patient for translucencies or special effects, so I tend not to apply translucent shades at the incisal edges for multiple unit cases.

The composite was applied in as few layers as possible, in accordance with the reverse triangle technique guidelines, to reduce the risk of incorporating microscopic air voids into the material.

### High-lustre finish

After final curing with glycerine gel, the URI was

## I am a passionate believer that the best things in life are simple!

shaped freehand with discs, facing the patient with him upright, to enable constant referral back to his face. Once the URI shape was satisfactorily completed, the process was repeated on the remaining teeth (Figures 12 and 13).

The occlusion was then checked in the intercuspal position, as well as in lateral and protrusive excursions. Minor adjustments were carried out until even contacts were created in the anterior region between canine to canine.

The front six teeth were polished using All Surface Access Polishers (ASAP) wheels and a felt wheel with polishing paste to create a high lustre (Figures 14-16).

A digital scan was taken and sent to IAS to create upper and lower indirect fixed-wire retainers, which took a week to be delivered. In the interim, the patient was provided with a temporary Essix retainer to wear 22 hours per day until the wire retainers could be fitted. The laboratory-produced wire retainers were extremely easy to place, as they are customised on prefabricated jigs.

Kulzer Venus Diamond Flow was used for its excellent strength and flowability to bond the lower wire retainer (Figure 17). Meanwhile, thin sections of Venus Pearl were used for the upper wire retainer (Figure 18), due to its easier manipulation and higher wear resistance. The upper wire retainer was fitted high, in accordance with the Dahl principle.

The patient will be seen every six months for

routine care and to monitor retention. The composite bonding will be polished at these appointments, and the patient has been advised to maintain whitening with Philips Zoom! Daywhite for three to six days at six-monthly intervals. He has also been instructed to wear Essix retainers every night once even contacts have been re-established, following the Dahl treatment method.

### Smile transformation in four months

The outcome was a dramatic transformation, quickly achieved with a conservative approach (Figure 19). In just over four months, all of the patient's concerns were able to be addressed with creation of a more symmetrical, harmonious smile (Figure 20).

The spacing had been closed in the upper arch, and the lower anterior crowding was relieved. The midline discrepancies had been corrected and the gingival zenith levels were also improved.

The patient was ecstatic when he saw the result (Figure 21). In particular, he was impressed with the level of shine achieved and was amazed at the smooth feel of the composite bonding. I personally put this down to the superior polishability of Venus Diamond. **D**

**THE AUTHOR IS** indebted to Dr Tif Qureshi at Dental Elegance for pioneering the ABB protocol and reverse triangle technique. He would also like to thank his assistant Ellie Hawkins, and colleagues Dr John Maveli and Dr Dan Patel for their continued support and guidance. For more details, email Dr Latiff at [hlatiff92@gmail.com](mailto:hlatiff92@gmail.com), visit [www.dentalelegance.co.uk](http://www.dentalelegance.co.uk), or write to Dental Elegance, 178 Blackfen Road, Blackfen, Sidcup, Kent DA15 8PT.



**Figure 20:** In just over four months, the patient's concerns were addressed, with creation of a more symmetric, harmonious smile



**Figure 21:** The patient was ecstatic when he saw the result