

CLINICAL

A quick, aesthetic restoration of a posterior tooth

Monik Vasant presents a composite posterior restoration case

A new patient in her early thirties attended for a check up. A routine radiograph revealed caries under the amalgam filling on the UR5. When advised that the tooth needed treatment, the patient revealed she had been unhappy with how it looked. The filling was very visible and shiny when she smiled. The dark appearance of the tooth made her self-conscious. The patient thought treatment would be long and expensive, so she hadn't bothered to ask.

The options were to have another amalgam filling or a composite restoration. The patient was advised that further composite treatment could be needed buccally to mask any remaining grey discolouration, if she was not satisfied with the outcome. As she was concerned about the appearance of the tooth, the patient did not want an amalgam filling and decided to have the composite restoration.

Preparation

After a local anaesthetic was given, rubber dam (Optidam) was placed, with a clamp on the UR6, exposing the upper right 4, 5 and 6. This was secured in place with floss ties. The old amalgam and caries were removed. The final portion of discoloured dentine was left behind as it was very deep, but the pulp was not exposed and it was still firm.

A sectional matrix band was then positioned mesially on the UR5, with a wedge and separation ring (V-ring). Initially, the enamel periphery alone was etched with 37% phosphoric acid for 15 seconds. Then etch was applied to the rest of the cavity for a further 15 seconds, prior to rinsing. A cotton pledget was used to protect the dentine during the drying process, to ensure dry enamel and moist dentine.

A two-bottle adhesive, with separate primer and adhesive, was used to complete the preparation. The dentine was primed and left for 30 seconds. The adhesive was placed on both the enamel and dentine, and allowed to sit for 30 seconds before curing.

Restoration

For posterior composite restorations, my first choice is Heraeus Kulzer's Venus Pearl. The enamel shades are more opaque and chromatic than other products, making it easier to block out any underlying discolouration. Even if adjustments to the restoration need to be made, it looks great. The handling of Venus Pearl is excellent. Its ideal consistency prevents slumping, while it is easy to manipulate and sculpt.

In this restoration, a small amount of Venus Flow base liner was placed and cured. This was to mask the greyness and dark discolouration from the base of the cavity.

Next, a thin layer of Venus Pearl A2 shade was applied to build up the mesial wall against the matrix. The height was built up to the level of the adjacent marginal ridge. The material was then manipulated with a sharp probe

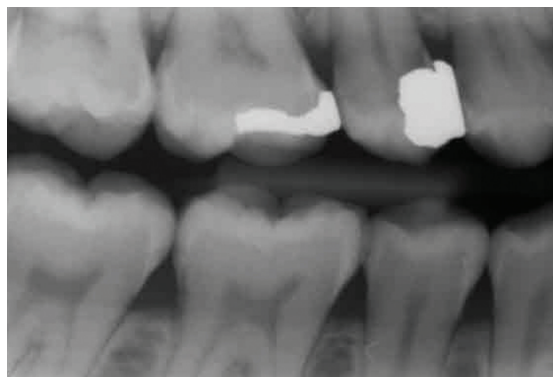


Figure 1: A routine X-ray revealed caries under the amalgam filling in the UR5

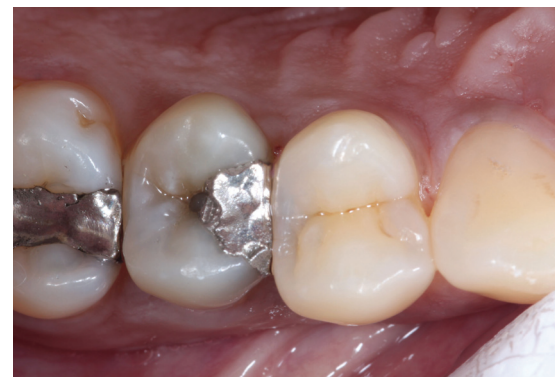

Figure 2: The UR5 filling was very visible when she smiled and the dark appearance made her self-conscious

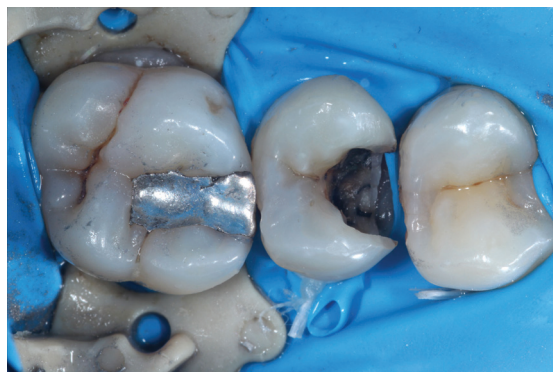

Figure 3: The old amalgam and caries were removed following rubber dam placement

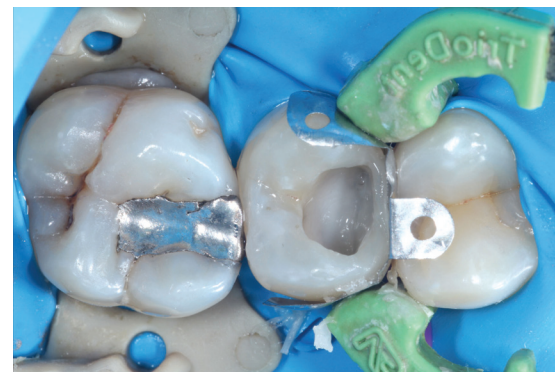

Figure 4: Heraeus Kulzer's Venus Pearl A2 shade was applied to build up the mesial wall

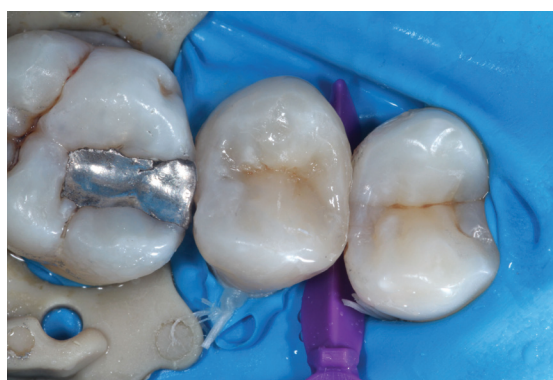

Figure 5: Separation of the masses was achieved by creating fissures down to the dentine layer and then stain was applied

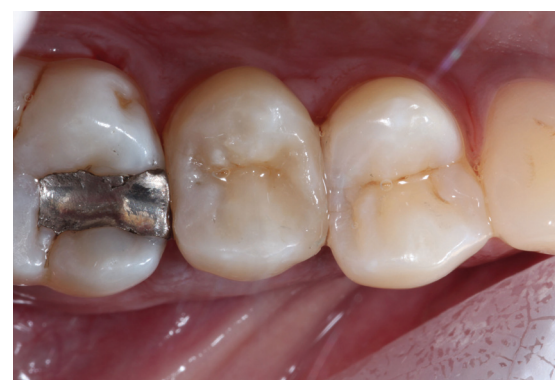

Figure 6: The patient was delighted with the result after having endured an unsightly amalgam filling for years

As she was concerned about the appearance of the tooth, the patient did not want an amalgam filling and decided to have the composite restoration

at a 45° angle. This ensured the edge of the wall was not straight and the natural curved shape of the marginal ridge was maintained. The dentine mass was built up in increments with Venus Pearl ODC shade (opaque dark chromatic).

Enamel A2 shade was placed over the occlusal surfaces cusp by cusp. Complete separation of the masses was achieved by creating fissures down to the dentine layer, using a sharp probe. Secondary anatomy was manipulated into the unset material before light curing.

A mix of Venus Color, 'corn' and 'choco' stains, was applied to the fissures using a probe, and pressed in with a long bristle brush. The excess was wiped away with a conventional micro-brush and the stain was cured. Highlights were placed on the ridges using Venus

Color 'white' mixed with a little 'corn', to give a milky colour. Final adjustments were carried out before rough, dry polishing. The restoration was then sealed with a protective clear coating, covered with glycerine and cured.

Outcome

In this case the clinical outcome was good. The tooth is regularly monitored for vitality and the patient hasn't had any problems with it.

As the caries was so deep, in the long term the tooth may require root canal treatment, but it is currently sound.

The patient was delighted with the result after having endured an unsightly amalgam filling for years. **D**



Dr Monik Vasant BChD MSc is the principal dentist at Freshdental, with clinics in Greater Manchester and London. He has a special interest in minimally invasive aesthetic dentistry.

Dr Vasant lectures on several postgraduate courses around the UK on restorative, adhesive dentistry and short-term orthodontics. In addition, he runs courses on direct and semi-direct composite bonding.